E.B.M.
Autologous bone grafting

Th. Bégué

Department of Orthopaedics and Trauma
Antoine Beclere Hospital
Univ Paris-Sud XI
Clamart, France

W, 45y. Open Fract IIIA
Devascularized diaphyseal segment

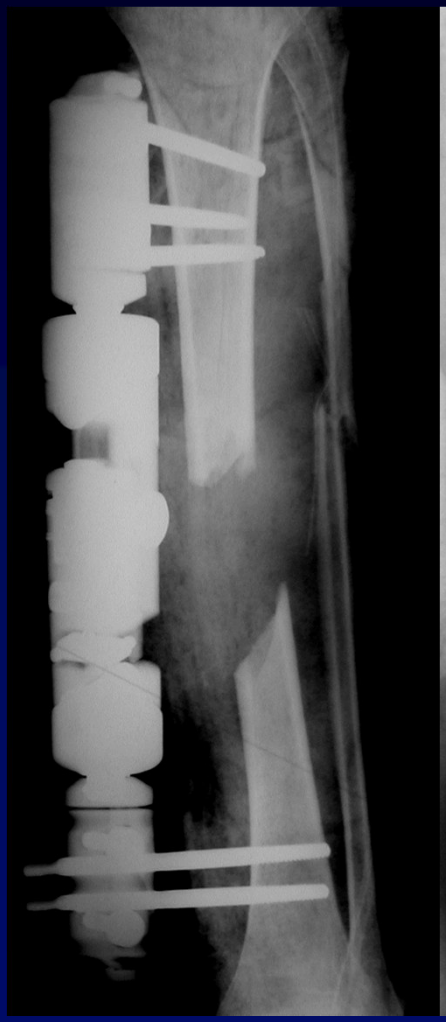

End result : 3y

Recombinant human bone morphogenetic protein-2: a novel osteoinductive alternative to autogenous bone graft ?
Szpalski M, Gunzburg R.
Acta Orthopaedica Belgica 2005; 71(2):133–48.

- **Autogenous bone grafts from iliac crest have been the gold standard for repair and reconstruction of bone**
- **however harvesting of the grafts from the iliac crest is associated with donor site morbidity, particularly chronic pain**
- **Limited amount of bone stock may be a concern in severe bone defects.**

Biological enhancement of tibial diaphyseal aseptic non-unions: the efficacy of autologous bone grafting, BMPs and reaming by products.

Kanakaris NK, et al.

Injury, 2007 May;38 Suppl 2:S65-75

- **Review of existing evidence for efficacy of reaming, autologous bone grafting, growth factors (BMP-2 and BMP-7) for aseptic tibial non-unions.**
- **Gold standard method in tibial non-union = autologous bone graft.**
- **Autogenous bone grafts possess osteoconductive, osteoinductive properties and osteoprogenitor cells.**
- **However, their harvesting is associated with high morbidity and many complications reaching percentages of 30%.**

Morbidity of bone harvest
Banwart, Spine, 1995

- 261 cases, 225 followed (86%)
  - 32-105 month follow-up
  - 45 droped for analysis (180)
- Ant and Post iliac crest
- No lesion of vessels, sciatic nerve, infection, hernia, meralgia, fracture.

Morbidity of harvest
Banwart, Spine, 1995

- Major Complications : 18 patients (10%)
  - 3 new surgery : wound pbs, hematoma
  - 12 esthetic concerns
  - 3 painful disorders
- Minor Complications : 70 patients (39%)
  - Cutaneous Dysesthesia temporary (20), definitive (50)
- Multivariance Analysis
  - Risk factors : female, age under 20 ans, separate incision

Morbidity after bone harvest
Ahlmann. JBJS (A). 2002

- 108 autograft after osteitis
- Comparison anterior iliac crest vs post
- Retrospective : 66 ant / 42 post
- Anterior iliac harvest more frequent
  - Minor Complic 15% vs 0%
  - Major Complic 8% vs 2%
- Pain and duration of pain
  - higher in anterior harvest

Harvest Morbidity
Siber. Spine 2003.

- 187 patients
  - Retrospective
  - Answer to Phone call
  - 4 y of follow-up
  - Anterior Iliac crest, Three cortices
- 134 correct answers
- Short term
  - 1.5% reop (infection, hematoma)
  - Difficulty for walking : 50.7%
  - Fistula : 7.5%

Harvest Morbidity
Siber. Spine 2003.

- Long term
  - 26.1% with persistent VAS > 3
  - 11.2% permanent pain medications
  - Discomfort
    - Walking: 12.7%
    - Hobby: 11.9%
    - Work: 9.7%
    - ADL: 8.2%
    - Sexual activity : 7.5%

Harvest Morbidity
Robertson. Spine 2001

- 106 patients
  - Prospective
  - Posterior Iliac crest. Lumbar surgery
  - Minor complications : 35%
    - Most frequent : Pain
  - Pain at 3 months
    - 12 % with VAS >3
    - 55% painless

BMP for fracture healing in adults Cochrane 2010

Bone morphogenetic protein (BMP) for fracture healing in adults (Review)

Garrison KR, Shemilt I, Donell S, Ryder JJ, Mugford M, Harvey I, Song F, Alt V

THE COCHRANE COLLABORATION®

BMP for fracture healing in adults Cochrane 2010

- BMP vs Surgery, vs Surgery + Bone graft, Bone substitutes
- ICBG considered as Gold Standard
- 11 RCT, 4 Economic studies
- Autograft gives similar results as BMP
- Donor site morbidity is the major adverse effect
- Discussion in « fractures at risk »

What's about R.I.A. ?





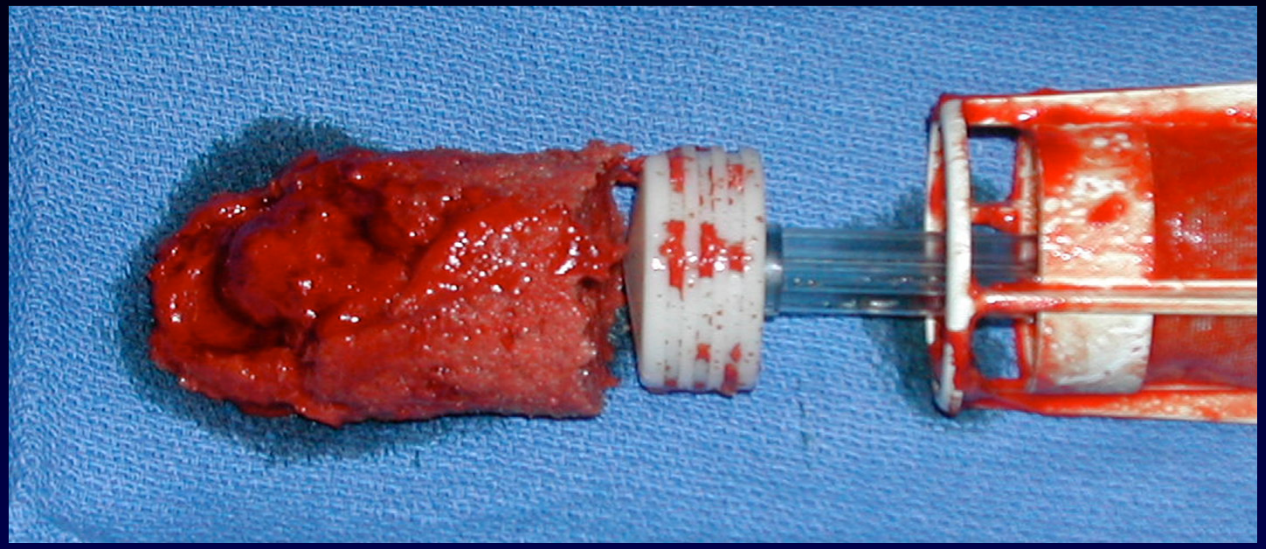

Finite elements model and experimental work for torsion biomechanical aspects after femoral reaming

F.X. Bulard, D. Mitton, P. Thoreux, T. Bégué, A.C. Masquelet

- Torque Forces after reaming with R.I.A.
- 7 cadavers (61-71a)
- Torque axis = femoral axis
- Spiroid Fracture
- Rigidity 393 Nm/rad, Torque 125 Nm, Angle 20°
- Less ++++ compared to results from Martens et al , J. Biomech, 1980 (562 Nm/rad, 183 Nm, 20°)
- Major concerns when reaming is of 15mm or above



Routine

MATLAB



Figure 17 : Fémur non alésé

Figure 18: Fémur alésé

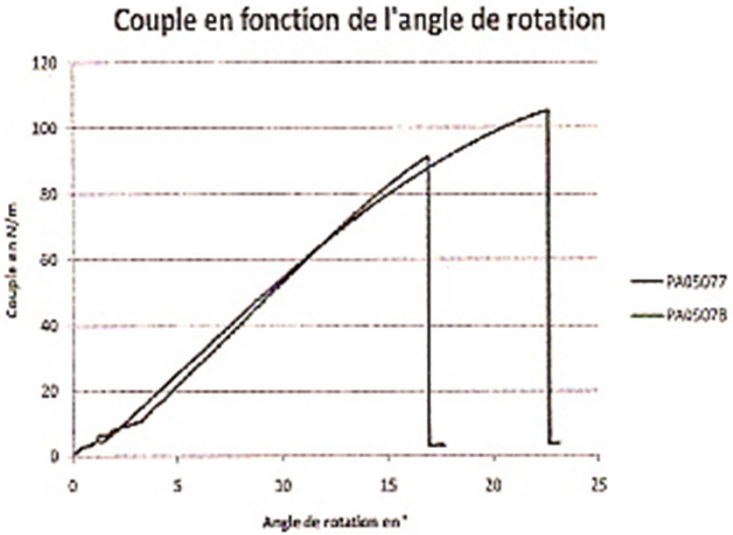

Figure 28 : Courbe PA05077 et PA05078

Les deux figures suivantes montrent le lieu de fracture pour un fémur pour le modèle numérique et lors de l'expérimentation.



Figure 31: Fracture PA05077



Figure 32 : Concentration de contrainte lors de la simulation PA05077

Technical Tricks When Using the Reamer Irrigator Aspirator Technique for Autologous Bone Graft Harvesting

Quintero AJ, Tarkin IS, Pape HC

J.O.T., 2010

- **Potential for unexpected events resulting from the sharp front-end cutting reamers that engage directly with the guidewire or bone.**
- **To help prevent sharp eccentric reaming with a prebent guidewire, we recommend regularly assessing the positioning of the guidewire through the frequent use of intraoperative fluoroscopy.**
- **Finally, it is important to be aware that the efficient suction device can lead to excessive blood loss.**
- **Adequate learning curve is necessary to minimize the risk of adverse events**

Conclusions

- Autologous Bone graft is the gold standard method for non-unions treatment
- Donor site morbidity must be included in the explanations for patients
- Other proposals still controversial
- RIA may lead to less complications, or new ones